

Challenges in Dental Imaging – Edge and Texture Analysis in Caries Detection

Mihaela IONESCU¹, Alin-Gabriel IONESCU^{1,*}, Horia MANOLEA¹, Anca TUDOR², Călin MUNTEAN², Oana VĂTĂMANU², Marius Eugen CIUREA¹, Ion ROGOVEANU¹, Cristin Constantin VERE¹

¹ University of Medicine and Pharmacy of Craiova, 2-4 Petru Rareș Street, 200349, Craiova, Romania.

² “Victor Babeș” University of Medicine and Pharmacy, 2 Piața Eftimie Murgu, 300041, Timișoara, Romania.

E-mail*: alinionescu81@yahoo.com

* Author to whom correspondence should be addressed; Tel.: +40724911230

Received: December 16, 2017 / Accepted: May 11, 2018 / Published online: June 30, 2018

Abstract

One of the most frequent diseases all over the world is represented by dental caries, hence it is of utmost importance to detect them as early as possible, in order to prevent massive tooth decay. Next to clinical examination, radiographic images are essential in identifying caries, especially for lesions located on the contact surface between the posterior teeth. Incipient caries are difficult to identify, sometimes even for specialists, so segmentation and detection through various image processing techniques may be useful. This paper presents an analysis of edge and texture parameters in X-rays containing caries, based on Sobel and Canny operators, Gabor filters and local binary pattern (LBP) operator. Our study set consisted in 80 X-rays from Bitewing Radiography Caries Detection Challenge 2015. Final results align with literature results and confirm the fact that caries segmentation in X-rays is a difficult task, with an average of less than 35% edge pixels correctly identified and poor results for texture segmentation; they also motivate us to refine our work in search of new algorithms and methods for caries segmentation and detection.

Keywords: Dental informatics; Diagnostic imaging; Caries; Edge detection

Introduction

Dental caries represents the loss of mineral within the tooth starting from the outer layers of the enamel, process known as demineralization. Caries seem to be one of the most frequent pathologies in dentistry, both for children and adults, usually with prevalence values over 20-30% in the majority of recent studies [1-4]. These values motivated both dentists and researches to identify various methods for caries detection in early stages, since this increases the chances for re-mineralization by applying preventive agents (usually fluoride) [5]. An early lesion is the first sign of the disease and it is difficult to identify, sometimes even for specialists. Diagnosis is performed by clinical examination, usually for larger lesions, and radiography, mostly from a bitewing perspective. A demineralization degree of approximately 40-50% is needed for a proper radiographic detection of caries. Also, radiography is indicated for lesions situated on the contacted surfaces between back teeth, where visual inspection is less likely to detect potential lesions. Caries may be classified as incipient or moderate (stages I and II), when they affect only the enamel; advanced caries (stage III) have perforated the enamel and penetrate less than half-way through the dentin layer, while severe lesions

(stage IV) penetrate more than half-way through the dentin. No matter the type of caries, an automatic detection process would provide dental practitioners with important clues in diagnosis and further treatment. In this paper, we performed an analysis of two basic imagistic parameters, in order to determine to which extent the caries region may be segmented from the main components of teeth. It is also important to mention that previous dentistry work affect the visual aspect, therefore increasing the complexity of automatic detection.

Material and Method

Our study set consisted of 80 bitewing images (all corresponding to individual patients) publicly available after Bitewing Radiography Caries Detection Challenge (within IEEE International Symposium on Biomedical Imaging 2015) [6]. Figure 1(a) presents one image included in this set. The organizers also provided ground truth images with a detailed analysis of the corresponding dental anatomy, for comparison and results evaluation. All teeth were divided in seven different structures: enamel, dentin and pulp as basic elements, completed by caries, crown, restoration, and potential treatments. In ground truth images, caries were emphasized with blue, as presented in Figure 1(b).

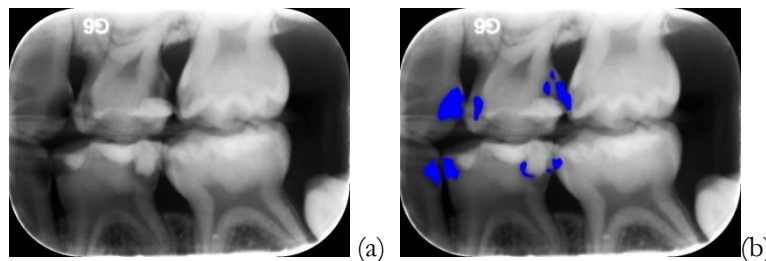


Figure 1. (a) Original image. (b) Image with emphasized caries regions

Bitewing X-rays are indicated in caries and decay detection, individually or between teeth, but also for modifications of bone density related to gum diseases, verification of marginal integrity for fillings, or dental crowns' fit. The bitewing perspective contains both upper and lower teeth from a specific area of the patient's mouth. They are not entirely visible from this perspective, but only from crown (top) and up to the supporting bone; root tips are not included. Given the graphical aspect of radiographic images, detecting the presence of caries is a difficult task, especially in early stages when the size of these lesions makes them barely visible. Moreover, noise (or unwanted signal) induced by the acquisition process affects image quality [7], thus increasing the complexity of this task.

However, current image processing techniques offer several possibilities to potentially achieve this goal. Previous studies [8-11] have indicated good results in identifying the general contour of teeth in dental X-rays, but failed to avoid noise detection and to correctly segment inner structures, thus still leaving place for improvements concerning the automatic detection of caries.

Our study is based on a Gabor filter (scale 2, frequency 0.5), Sobel and Canny operators as edge detectors, and Local Binary Pattern (LBP) operator for texture. We have also included a pre-processing phase prior to feature analysis, based on a median filtering algorithm, in order to reduce the noise included in the test images. Caries edge detection accuracy was computed at pixel level, considering as reference the ground truth images provided in the original dataset.

All 80 images from our data set were submitted to the same processing phases: initial noise reduction, followed by edge detection, with all three operators, and texture detection with LBP. Then, all images were compared with the ground truth images (containing correct identification of dental caries). We subsequently performed an analysis of every lesion: for every pixel of each detected edge, we formed a pair with a pixel on the real edge, such as to align them with the center of the real segmented area, and we computed the Euclidean distance between the two pixels. Also, for every pair, we allowed a distance variation of less than 6.5% from the total surface of the lesion (measured from the ground truth image). All images belong to unique patients, so the result accuracy should measure the ability to correctly identify the shape of caries, in order to perform an appropriate

estimate of their depth, thus to ensure a proper diagnostic performance and full support for the examination process.

Results

Among all three edge detection methods, none showed very good results in segmentation, but this basically aligns with the overall competition results. The general aspect of radiographies simply presented too many gradient variations that were interpreted as borders, leading to images altered by false edges. Pulp and dentin were not delimited as single structures, a lot of false edges being found within their perimeters. Caries were partially identified, thus the edge detection process was not enough to differentiate them as individual lesions of the tooth. The connection with texture data did not provide extra information that would lead to better segmentation. The average accuracy values for each edge detector are given in Table 1. Figures 2(a), (b) and (c) present an example of edge detection with all 3 detectors, for the same image.

Table 1. Average accuracy for caries edge detection

Edge detection	Average accuracy (%)
Sobel edge detector	12.53 ± 1.25
Canny edge detector	19.36 ± 2.18
Gabor filter phase response edge detector	34.78 ± 4.14

Texture detection in the original images also indicated extremely poor results in caries segmentation (with an average of 2.47%±0.11%). Based on our study set, it would appear that there is no significant difference between caries and other image components (enamel, dentin, pulp) in terms of texture (Figure 2). The only consistent difference seems to be with the empty space between the teeth, as shown in Figure 2(d), especially for large cavitated lesions.

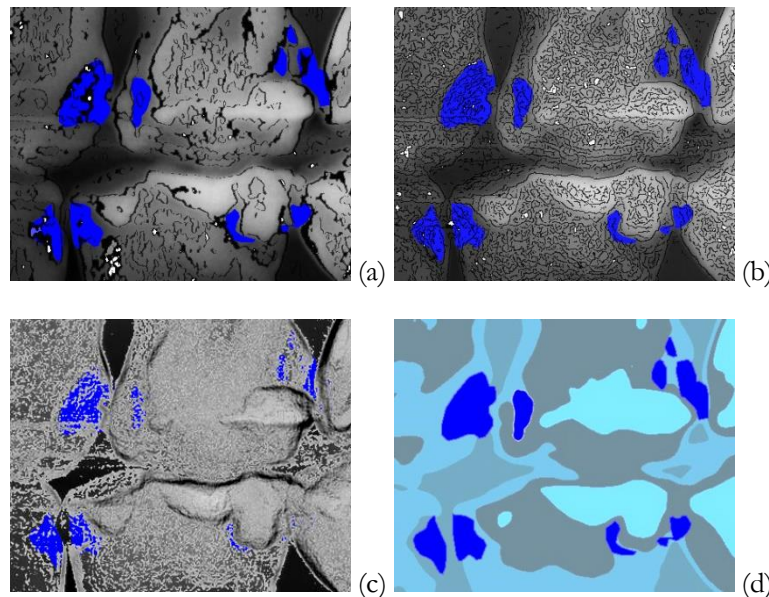


Figure 2. Edge detection with (a) Gabor filter phase response. (b) Canny edge detector. (c) Sobel edge detector. (d) Texture detection.

Based on the caries classification, stages I and II seem to be easier to segment, as their edges would separate regions characterized by high spatial gradient values (dental caries aspect compared

with enamel aspect). Also, the superior margins of highly cavitated lesions are easily to detect, compared to superficial and non-cavitated caries.

Discussion

Dental radiographic images are based on an X-ray beam passing through certain areas of the patient's mouth and penetrating the oral structures, before reaching a photographic plate or a set of digital sensors. X-rays are basically electromagnetic radiation which is attenuated by the encountered tissues before reaching a stop point. The degree of attenuation depends on the various anatomical densities and the absorption level of the blocking elements; soft tissues determine a less attenuated beam, thus forming a darker region within the captured image, while hard tissues absorb much of the radiation, leading to lighter areas within the image. The penetrating power of the beam is proportional with the average photon energy determined by the x-ray tube voltage, so physical characteristics also influence the final output. For digital X-rays composed by individual pixels, the value of a pixel is determined by the amount of photons detected from the beam [7].

Caries are induced by specific types of bacteria [12] that may produce acid in the presence of sugar and carbohydrates, thus penetrating the enamel and dentin, if not treated in time. This type of lesion implies loss of minerals and the creation of cavities within the tooth. As the tissue was consumed, the visual aspect of that specific area in an X-ray image is dark, since there is basically no attenuation of the beam. The acid penetration is not uniform within the cavity, thus the edge of the lesion related to the tooth enamel or dentin is not well defined. The border area between lesion and tooth is characterized by shades of gray, depending on the degree of beam attenuation, and it shows an actual progression from darker shades (cavity) to lighter shades (tooth layer). Numerous scientific papers indicate both Canny and Sobel as useful in edge detection in general X-ray images, mostly indicating clear bones fractures. For teeth segmentation however, the results are not satisfactory enough, a fact confirmed by our study as well. The essence of the edge detection process is to identify sudden changes in the image intensity. Algorithms based on these two operators compute an approximation of the first derivative for the corresponding image, creating a filter. The original image is convolved with this filter. The gradient is computed using a 3×3 neighborhood and the associated discrete differences between rows and columns. The gradient magnitude is then submitted to thresholds, leading to a binary output image comprised by the detected edges.

However, teeth are composed by multiple structures defined by similar densities, so specific dental X-ray images contain slightly different shades of gray. Even if caries express dark regions within the tooth area, according to their volume and depth, gradient magnitude calculation does not seem to be enough to delimitate them from other regions; this would explain why the Sobel detector showed such poor results in edge detection, being mainly based on this parameter. Since the Canny detector implies several extra-steps (noise filtering through a Gaussian filter, non-maximum suppression and hysteresis based on two thresholds), it showed improved results in accuracy, but still not good enough to reflect confidence in a segmentation process based only on edge detection. The phase response of the Gabor filter was better than the previous two operators, identifying more correct edge pixels. In this case, the final result was also based on a convolution of the original image with a filter, only that this filter is based on a specific frequency and angle that allowed less sensitivity to gradient variations, thus identifying less false edges in the same layer of the teeth, while detecting more clear edges between teeth structures. Noise is also responsible both for false edges and lack of real edge detection. X-ray noise is mostly the result of physical parameters: voltage and current within the x-ray tube, completed by the exposure time [7]. Slight variations in pixel values may either be fine details with low contrast within the real image (thus true artifacts of the teeth), or noise induced by the physical equipment. Tube voltage also affects image contrast, which is a key parameter in edge detection. Low-contrast details may be very similar to noise, thus it is possible to miss small lesions, non-cavitated caries, during the noise removal phase. The overall analysis of the image indicated that this pre-processing phase is important, but it led to a lack of fine edge detection. An equitable tradeoff between these processes is hard to achieve. Detection performance was also dependent on the lesion stage. A highly cavitated lesions would indeed present darker regions at enamel level, where the edge

detection process was more accurate, while a non-cavitated one was sometimes impossible to identify through edge detection.

A brief look in literature regarding automatic caries detection shows that this is a difficult task to perform. Caries' margins are not clearly defined and their texture is quite similar to that of the surrounding elements. There are several factors that influence the aspect of caries in radiography, even for the same lesion, like: speed film, degree of demineralization, position, tooth thickness, 2D aspect of the radiography, x-ray beam angle or exposure factors. According to [6], the main characteristics in automatic detection are the need for invariance to translation, followed by robustness to gray value variations, rotations and deformations (mainly elastic deformations). An ideal algorithm should take into account both image parameters and equipment settings. Pre-processing phases, such as noise reduction or image sharpening, are needed before edge detection.

Automatic segmentation is useful in diagnosis and the elaboration of a treatment plan. Also, extremely small lesions that do not require immediate treatment may be monitored over a period of time. Periodical X-rays of the same area, though not indicated due to increased exposure times, may reveal caries progression rate. Detection would be easier in this case, as the location of the lesion is known and only the depth needs further evaluation. In this case, volume error would be indicated for comparison of current and past radiographies. Thus, finding a universal, robust and effective method may be harder than it would seem at a first glance and it is also dependent upon the equipment used for image acquisition and generation.

Our study proved that basic edge and texture operators do not provide satisfactory results. Future studies may include progress tracking and improved detection rates for non-cavitated caries. Also, we plan to introduce a new pre-processing phase, in order to increase the sharpness of important edges, and minimize the false positive edges.

Conclusion

Caries detection in radiographic images is still a challenging process, but there are promising directions for future development. With our study, we have showed that noise reduction through a median filtering algorithm still left a significant amount of noise in x-rays, leading to false edges detected with all three tested edge detectors (Sobel, Canny, Gabor filters). Also, simple edge detection and texture operators (through LBP) were not enough to provide clear segmentations of caries in dental X-rays. Further research needs to be performed, both for the pre-processing phase, in order to reduce noise and emphasize important contours, as well as for the actual caries identification, for better detection accuracy.

References

1. Gomez J. Detection and diagnosis of the early caries lesion. *BMC Oral Health*. 2015;15(Suppl 1):S3. doi:10.1186/1472-6831-15-S1-S3.
2. Rafael da Silveira Moreira. *Epidemiology of Dental Caries in the World*. Oral Health Care - Pediatric, Research, Epidemiology and Clinical Practices. Prof. Mandeep Viridi (Ed.), ISBN: 978-953-51-0133-8, InTech. 2012. pp. 149-168.
3. Reich E. Trends in caries and periodontal health epidemiology in Europe. *International dental journal* 2001;51:392-398.
4. Dye BA, Thornton-Evans G, Li X, Iafolla TJ. Dental caries and sealant prevalence in children and adolescents in the United States, 2011–2012. NCHS data brief, no 191. Hyattsville, MD: National Center for Health Statistics. 2015.
5. Lagerweij MD, Cate JM. Remineralisation of Enamel Lesions with Daily Applications of a High-Concentration Fluoride Gel and a Fluoridated Toothpaste: An in situ Study. *Caries Res* 2002;36:270-274.

6. Wang CW, Huang C, Lee J, Li C, Chang S, Siao M, Lai T, Ibragimov B, Vrtovec T, Ronnerberger O, Fischer P, Cootes T, Lindner C. A benchmark for comparison of dental radiography analysis algorithms. *Medical Image Analysis* 2016;31:63-76.
7. Huda W, Abrahams RB. Radiographic Techniques, Contrast, and Noise in X-Ray Imaging. *American Journal of Roentgenology* 2015;204(2):W126-W131.
8. Croock MS, Khudhur SD, Taqi AK. Edge Detection and Features Extraction for Dental X-Ray. *Eng. &Tech.Journal* 2016;34(13):2420-2432.
9. Lakhania K, Minochaa B, Gugnani N. Analyzing edge detection techniques for feature extraction in dental radiographs. *Perspectives in Science* 2016;8:395-398.
10. Senthilkumaran N. Edge Detection for Dental X-ray Image Segmentation using Neural Network approach. *The International Journal of Computer Science & Applications (TIJCSA)*. 2012;1(7):8-13.
11. Grafova L, Kasparova M, Kakawand S, Prochazka A, Dostalova T. Study of edge detection task in dental panoramic radiographs. *Dentomaxillofac Radiol.* 2013;42:20120391. doi: 10.1259/dmfr.20120391
12. Gomez J. Detection and diagnosis of the early caries lesion. *BMC Oral Health*. 2015;15(Suppl 1):S3. doi: 10.1186/1472-6831-15-S1-S3